

**9**

STAINING OF PBF AND INTERPRETATION OF NORMAL AND ABNORMAL RED CELL MORPHOLOGY

9.1 INTRODUCTION

A peripheral blood smear (peripheral blood film) is a glass microscope slide coated on one side with a thin layer of venous blood. The slide is stained under a microscope. Examination of a stained peripheral smear is an integral part of laboratory evaluation of patients. It provides information on red cells, leucocytes and platelets and is used to supplement the information provided by automated hematology analyzers. Any parasite if present, can be identified on the smear. Abnormal cells can also be detected in patients with hematological malignancies.



OBJECTIVES

After reading this lesson, you will be able to:

- describe the principle of staining
- explain red cell abnormalities seen on the smear and their interpretation

9.2 STAINING OF PERIPHERAL SMEAR

Peripheral blood smears can be prepared from fresh blood to which no anticoagulant is added or from EDTA blood. Clean glass slides should be used for making blood films. Each smear should be labelled with the patient number.

MODULE

Hematology and Blood
Bank Technique



Notes

Staining of PBF and Interpretation of Normal and Abnormal Red Cell Morphology

Smears are routinely stained with **Romanowsky stains** with very good results. These dyes have the property of making subtle distinction in shades of staining. They also stain granules differentially.

Commonly used Romanowsky stains

1. Giemsa
2. Wright
3. Leishman
4. Jenner's

Of these, Leishman and Wright are widely used in routine staining. However, the results are inferior to Giemsa and Jenner.

The International Council of Standardization in Hematology advocates a combination of pure **azure B and eosin Y** in the stain to be used.

Azure B being a basic dye binds to anionic molecules such as phosphate group of DNA and proteins of the cell nuclei. Eosin Y is an acidic dye and binds to basic molecules such as Hemoglobin and cationic sites on proteins. This difference in binding of the dye to various structures of the cell results in staining of that cell component with particular dyes. Thus red cells stain pink, the leucocyte cytoplasm is light pink, the nuclei are purplish black and the granules of the different leucocytes stain a different color.

The **advantages** of using this combination are that the procedure can be standardized and produces consistent results from batch to batch. The **disadvantage** is that the stain is expensive.

9.3 MAKING A PERIPHERAL BLOOD SMEAR

Examination of a stained peripheral smear is an integral part of laboratory evaluation of patients. It provides information on red cells, leucocytes and platelets and is used to supplement the information provided by automated hematology analyzers. Any parasite if present, can be identified on the smear. Abnormal cells can also be detected in patients with hematological malignancies.

This is possible only if the peripheral smear is well prepared.

Sample

Peripheral blood smears can be prepared from fresh blood to which no anticoagulant is added or from EDTA blood. Clean glass slides should be used for making blood films.



Notes

Method

1. Place a 1" × 3" glass microscope slide on a counter top of a laboratory bench. If frosted slides are used, the frosted end should face upward.
2. Write the laboratory number of the patient on the slide.
3. Place a 2 - 3 mm drop of blood approximately 1/4" from the edge, using a glass capillary tube.
4. Hold the slide by the narrow side between the thumb and forefinger of one hand at the end farthest from the frosted end.
5. Grasp a second slide ("spreader slide") between the thumb and forefinger of the other hand.
6. Place the edge of the spreader slide on the lower slide in front of the drop of blood (side farthest from the frosted end).
7. Pull the spreader slide toward the frosted end until it touches the drop of blood. Permit the blood to spread by capillary motion until it almost reaches the edges of the spreader slide.
8. Push the spreader slide forward at a 30° angle with a rapid, even motion.

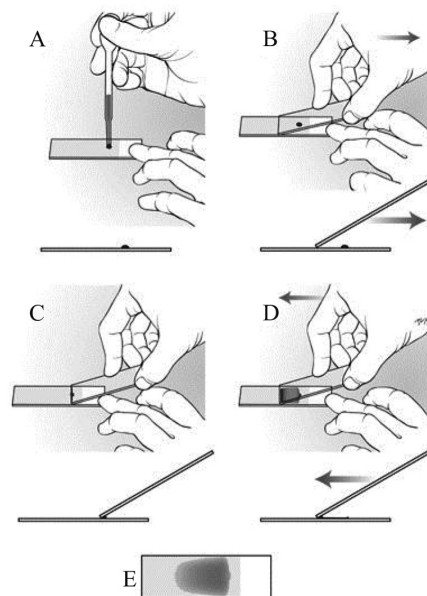


Fig. 9.1

- A : Place a drop of blood on the slide
- B : Hold the spreader as shown
- C : Pull the spreader over the drop of blood so that it spreads
- D : Push the spreader with a firm motion
- E : This is how the prepared film appears

MODULE

Hematology and Blood
Bank Technique



Notes

Staining of PBF and Interpretation of Normal and Abnormal Red Cell Morphology

9.4 MAKING STAIN SOLUTION

Wright stain

This is available commercially in powder form. Take 2.5g of powder and add 2.5L of methanol to it. Shake well. Keep the stain for 4-5 days for maturation. Filter the stain prior to use.

Giemsa stain

Take 1g of Giemsa powder in a conical flask. Add 100ml of methanol and warm the mixture to 50°C. Keep for 15 min. Shake occasionally. Filter and keep for few hours before using.

9.5 STAINING PERIPHERAL BLOOD SMEARS

Peripheral blood smears are stained with Romanowsky dyes.

The method of **Wright staining** is described.

Reagents required

1. Wright stain
2. Buffer water pH 6.8 This has

Solution A Potassium dihydrogen phosphate 9.1g/L

Solution B Di sodium hydrogen phosphate 9.5g/L

Mix 50.8ml of solution A and 49.2ml of solution B.

Method

1. Make a smear and air dry it.
2. Place the smear on a staining rack. Flood it with Wright stain and leave for 2 minutes. This is the time required for fixation(methanol acts as a fixative).
3. Add twice the amount of buffered water, pH 7 from a plastic wash bottle.
4. Leave for 10 minutes.
5. Wash the stain with buffered water till the smear has a pinkish tinge.
6. Wipe the back of the smear and stand upright to dry.

Precautions

- stain films as soon as possible after they have been dried.

Staining of PBF and Interpretation of Normal and Abnormal Red Cell Morphology

- do not leave the smears unfixed for more than a few hours. If smears are left unfixed for a long time, there is distortion of cellular morphology. Also, dried plasma stains the background of the smear a pale blue. If a delay is expected always fix the smear.
- the staining rack should be leveled.
- do not let the stain solution dry over the smear.

Giemsa staining

The slides are fixed in methanol first. The stain is poured over the slide and kept for 20 min. the smear is washed as above.



Fig. 9.2: Peripheral blood film before and after staining



INTEXT QUESTIONS 9.1

1. & can be detected by peripheral blood smear.
2. is routinely used in peripheral smear.
3. is a basic dye used in staining.
4. is an acidic dye used in staining.

9.6 INTERPRETATION OF RED CELL MORPHOLOGY ON THE PERIPHERAL SMEAR

Normal

Normal red cells appear well spread. The inner one third of each cell is devoid of hemoglobin and appears clear. There is very little variation in size or shape of normal red cells.

MODULE

Hematology and Blood Bank Technique



Notes

MODULE

Hematology and Blood
Bank Technique



Notes

Staining of PBF and Interpretation of Normal and Abnormal Red Cell Morphology

Anisocytosis

This means that the red cells are showing variation in size. It can be due to larger red cells or macrocytes or smaller red cells (microcytes).

Poikilocytosis

This refers to variation in shape of red cells. It can be seen in nutritional anemias, thalassemia and other hemolytic anemias.

Macrocytes

As the name suggests, these are red cells which are larger in size. They are found in

- megaloblastic anemia
- aplastic anemia
- myelodysplastic syndromes
- chronic liver disease



INTEXT QUESTIONS 9.2

Match the following

- | | |
|-------------------|-------------------------------|
| 1. Anisocytosis | (a) Cells are larger in size |
| 2. Poikilocytosis | (b) Cells are smaller in size |
| 3. Macrocytes | (c) Cell vary in shape |
| 4. Microcytes | (d) Cell vary in size |

Microcytes

These are red cells which are smaller in size. They are seen in

- iron deficiency anemia
- anemia of chronic disease
- thalassemia
- other hemoglobinopathies
- sideroblastic anemia

Hypochromia

It refers to the presence of red cells in which the area of central pallor is increased. It is seen in

- iron deficiency anemia
- anemia of chronic disease

- thalassemia
- other hemoglobinopathies
- sideroblastic anemia

Polychromasia

This appearance is of reticulocytes which appear pale blue on smears fixed and stained subsequently. So in patients with reticulocytes an increased number of polychromatophils are seen in the smear. They can be seen in

- hemolytic anemias
- nutritional anemias after treatment with hematinics

Target cells

These are cells in which there is a central round stained area and a peripheral rim of hemoglobin which are separated by non staining cytoplasm.

They are found in

- chronic liver disease
- iron deficiency anemia
- thalassemia
- other hemoglobinopathies

Spherocytes

These are spheroidal red cells with a regular outline. They are seen in

- hereditary spherocytosis
- immune hemolytic anemia
- hemolytic disease of the new born
- bacterial toxins

Basophilic stippling

This means the presence of numerous blue granules in the red cells. They are found in

- thalassemia
- lead poisoning
- unstable hemoglobins
- megaloblastic anemia

MODULE

Hematology and Blood
Bank Technique



Notes

MODULE

Hematology and Blood Bank Technique



Notes

Staining of PBF and Interpretation of Normal and Abnormal Red Cell Morphology

Howell Jolly bodies

These are nuclear remnants and are present singly in a small number of red cells. They are basophilic and are seen in

- after splenectomy
- pernicious anemia

Agglutination

This refers to clumping together of red cells as seen in auto immune hemolytic anemia.

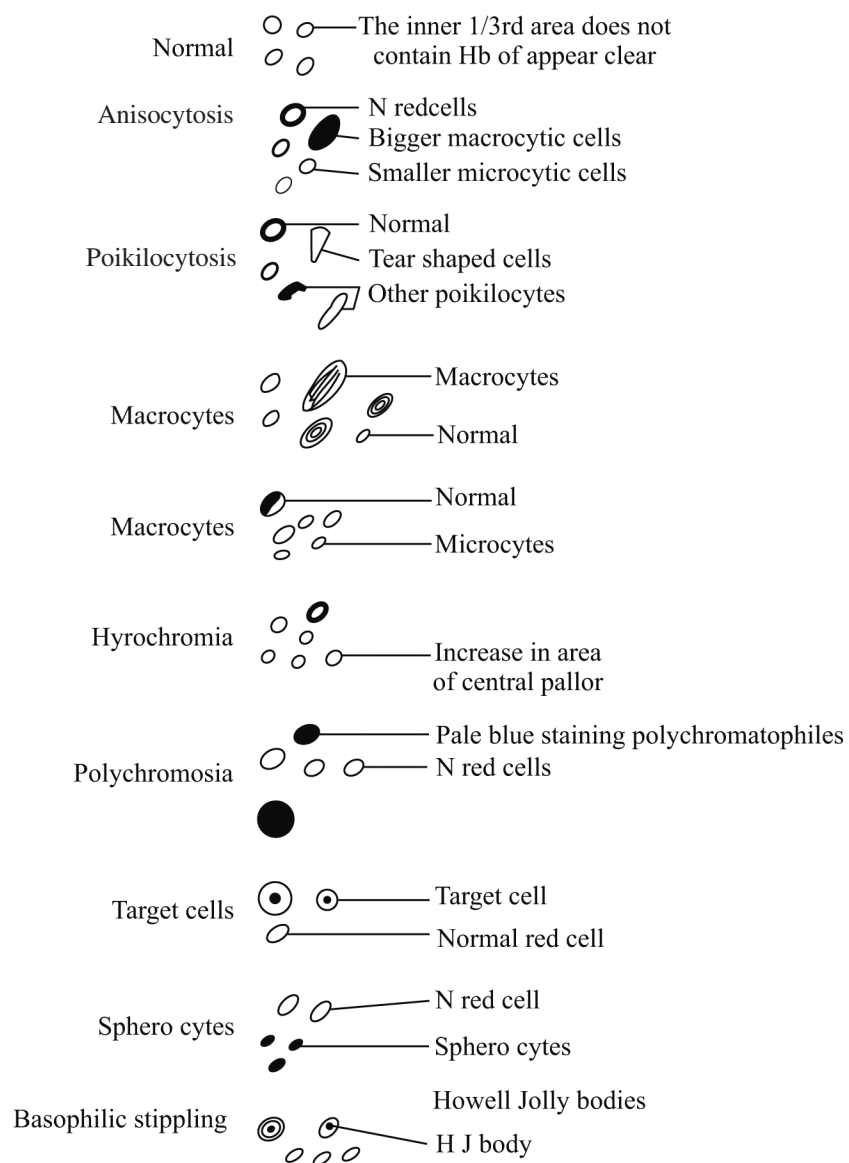


Fig. 9.3: Interpretation of red cell morphology

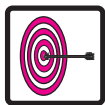

INTEXT QUESTIONS 9.3

1. Macrocytosis is seen in
 - (a) Megaloblastic anemia
 - (b) Iron deficiency anemia
 - (c) Thalassemia
 - (d) All of the above
2. Polychromasia represents
 - (a) Nucleated red cells
 - (b) Leucocytes
 - (c) Reticulocytes
 - (d) None of the above
3. The fixative present in Leishman stain is
 - (a) Methanol
 - (b) Ethanol
 - (c) None of the above
 - (d) Either of the above



Notes



WHAT HAVE YOU LEARNT

- Peripheral blood smears are stained with Romanowsk stains which include Leishman, Wright, Giemsa and Jenner's. They contain a mixture of azure B and Eosin Y. Of these, Leishman and Wright stains are commonly used. Several morphologic abnormalities can be seen in the red cells each of which are seen in specific conditions.



ANSWERS TO INTEXT QUESTIONS

9.1

1. Parasites & abnormal cells
2. Romanowsky stain
3. Azure B
4. Eosin Y

9.2

1. d
2. c
3. a
4. b

9.3

1. (a) Megaloblastic anemia
2. (c) Reticulocytes
3. (a) Methanol